

## A brief study on human bone anatomy and bone fractures

<sup>1</sup> N.Umadevi , <sup>2</sup> Dr.S.N.Geethalakshmi

<sup>1</sup> Head, Dept. of Computer Science and IT  
Sri Jayendra Saraswathy Maha Vidyalaya College of Arts and Science  
Coimbatore – 641 005.

<sup>2</sup> Associate Professor, Dept. of Computer Science  
Avinashilingam University For Women  
Coimbatore – 641 043.

<sup>1</sup>umadevigayathri@rediffmail.com, <sup>2</sup>snggeethalakshmi@yahoo.com

**Abstract.** The rapid and continuing progress in computerized medical image reconstruction and the associated developments in analysis methods and computer-aided diagnosis have propelled medical imaging as one of the most important sub-fields in scientific imaging. One important area is the fracture detection from x-ray images, where automated tools are used to detect fractures. In order to develop an automated fracture detection system, a clear understanding of human skeletal system, bone and fractures is required. This paper provides description on each of these topics.

**Keywords:** Human Skeletal System, Bone Classification, Long Bone, Fracture Types

### 1 Introduction

The rapid and continuing progress in computerized medical image reconstruction and the associated developments in analysis methods and computer-aided diagnosis have propelled medical imaging as one of the most important sub-fields in scientific imaging. Medical image processing consists of techniques and algorithms that can be used in various medical domain including trauma centre, orthopedic, pain management and vascular and non-vascular. They have the advantage of aiding healthcare professionals to quickly diagnose a disease in an accurate and efficient manner. Using advanced technology to increase the speed and accuracy of diagnosis in a trauma environment is the most frequently used application and helps in identifying fractures and sprains. An orthopedic surgeon could utilize these tools for alignment purposes as in hip and fracture pinning, thus saving time without having to reposition the patient or imaging device.

Today, India is the second most populous country in the world [3]. Fracture rates have gone up threefold over the last 30 years in India. Around 4.4 lakhs Indians get fractures every year, a figure set to hit 6 lakhs in 2020. Indians have 15% lower bone mineral levels than Westerners and therefore fractures happen 10-20 years earlier. More than 80% of urban Indians have Vitamin D deficiency and are at risk of fracture. In the total population, around 50 million Indians are believed to be vulnerable to fractures [5]. More serious is the fact that Indians are prone to fractures at a much younger age than their Western counterparts. Endocrinologist Dr. Ambrish Mithal, the man who installed India's first bone density measuring system in 1997, predicts that over 50 % of the world's fractures are expected to occur by 2050. Fractures feature more and more in Indian hospital records. Any big hospital in India, on an average day, gets about 75 fresh fracture cases, with 5 to 8 bone surgeries, says experts. As per the MCCD reports, in India, fractures constituted 7.5% of total injuries fractures of the skull and face and lower limbs accounted for 52% and 24%, respectively.

Fractures of the tibia and the fibula are the subject of ongoing controversy and discussion. Despite newer innovations in implants and external fixation devices, tibial fractures essentially remain unresolved; they are among the most challenging fractures to be treated by an orthopedic surgeon. These injuries are different and variable in presentation, and their outcomes are unpredictable. Globally, according to the National Center for Health Statistics, the occurrence rate for tibia, fibula, and ankle fractures is 492,000 per year in the United States [9]. Tibia and fibula fractures in the same time period resulted in 77,000 hospitalizations, accounting for 569,000 hospital days with an average length of stay of 7.4 days, and in 825,000 physician office visits. Tibial fractures are the most common long bone fractures [10]. Fractures of bone are a common affliction, accounting for approximately 20% occupancy of hospital wards at any given time [2] and worldwide, women have a 30–40% lifetime risk of suffering an osteoporotic fracture, while men have a lower risk of 13%. The incidence of tibial fractures has increased to approximately 500,000 cases in the United States per year. On average, almost 26 tibial fractures occur per 100,000 populations per year.

Owing to this great demand, the focal point of many researches that are involved in developing such tools is the identification of bone fractures from medical images. These tools involve analyzing the bone images and determine the presence or absence of fractures. Thus, to develop an efficient and effective fracture bone detection system, it is imperative to have sound background knowledge on human bone anatomy and details regarding the various bone fractures. This paper provides details regarding bone anatomy in detail with emphasis on leg bone. The fractures discussed in this paper are also restricted to long bones. The rest of the paper is discussed as follows. Section 2 presents general details on human skeletal system while Section 3 provides a discussion on leg bone structure. Details regarding bone fractures and types of long bone fractures are given in Section 4 and Section 5 concludes the paper.

## **2 Human Skeletal System**

Human skeletal system is the system of bones, associated cartilages and joints of human body. Skeleton is defined as the hard framework of human body around which the entire body is built. Almost all the hard parts of human body are components of human skeletal system. Joints are very important because they help the skeleton system to move at different locations. The skeleton system serves 6 major functions to human body [7].

1. **Support** : The skeleton provides the framework which supports the body and maintains its shape. The pelvis and associated ligaments and muscles provide a floor for the pelvic structures. Without the ribs, costal cartilages and the intercostal muscles the heart would collapse.
2. **Movement** : The joints between bones permit movement, some allowing a wider range of movement than others, e.g. the ball and socket joint allows a greater range of movement than the pivot joint at the neck. Movement is powered by skeletal muscles, which are attached to the skeleton at various sites on bones. Muscles, bones, and joints provide the principal mechanics for movement, all coordinated by the nervous system.
3. **Protection** : The skeleton protects many vital organs like, the skull protects the brain, eyes, and the middle and inner ears, the vertebrae protects the spinal cord, the rib cage, spine, and sternum protect the lungs, heart and major blood vessels, the clavicle and scapula protect the shoulder, the ilium and spine protect the digestive and urogenital systems and the hip, the patella and the ulna protect the knee and the elbow respectively, the carpals and tarsals protect the wrist and ankle respectively.
4. **Blood cell production** : The skeleton is the site of haematopoiesis, which takes place in red bone marrow.
5. **Storage** : Bone matrix can store calcium and is involved in calcium metabolism, and bone marrow can store iron in ferritin and is involved in iron metabolism. However, bones are not entirely made of calcium, but a mixture of chondroitin sulfate and hydroxyapatite, the latter making up 70% of a bone.
6. **Endocrine regulation** : Bone cells release a hormone called osteocalcin, which contributes to the regulation of blood sugar (glucose) and fat deposition. Osteocalcin increases both the insulin secretion and sensitivity, in addition to boosting the number of insulin-producing cells and reducing fat storage [8].

## 2.1 Components of Human Sketeton

Human skeleton is composed of three main components, namely, bones, associated cartilages and joints.

- **Bones** : Bone is a tough and rigid form of connective tissue. It is the weight bearing organ of human body and it is responsible for almost all strength of human skeleton. As these are the main study area, it is discussed separately.

- **Cartilages :** Cartilage is a type of connective tissue composed of special cells known as chondrocytes along with collagen or yellow elastic fibers. The fibers and the cells are embedded in a firm gel like matrix rich in mucopolysaccharides. Cartilage is not as hard and rigid as bone. It is much more flexible and elastic.

There are three types of cartilage, namely, Hyaline cartilage, Fibrous cartilage and Elastic cartilage [6]. Hyaline cartilage has very thin fibers having same refractive index as the matrix of the cartilage and thus these fibers are not seen. Hyaline cartilage is the articular cartilage of long bones, sternum, ribs etc. Its color is bluish white and it is flexible. Fibrous cartilage has numerous white fibers. It is present in the symphysis pubis, and sternoclavicular joint etc. Its color is glistening white and the appearance is opaque. Elastic cartilage has numerous yellow elastic fibers. It is present in the ear pinna, external auditory meatus, Eustachian tubes, and epiglottis etc. Its color is yellowish and the appearance is opaque.

Joints are important components of human skeleton because they make the human skeleton mobile. A joint occurs between "two or more bones", "bone and cartilage" and "cartilage and cartilage". Joints can be classified either by structure or by function. The functional classification is based on the amount of movement allowed at the joint and are classified as synarthroses (no movement), amphiarthroses (small amount of movement) or diarthroses (variety of movements). The structural classification focuses on the material binding the bones together, as well as the presence or absence of a joint cavity. They are classified as fibrous (no movement), cartilaginous joints (small amount of movement), synovial joints (variety of movement).

#### *(ii) Divisions of Human Skeleton*

Human skeleton can be divided into two divisions, namely, Axial and Appendicular skeleton (Figure 1) [4]. Axial skeleton forms the axis of human body. It consists of Skull, vertebral column and thoracic cage. Appendicular Skeleton is the skeleton of appendages of human body. It consists of Shoulder girdle, Skeleton of upper limb, Pelvic girdle and Skeleton of lower limb.

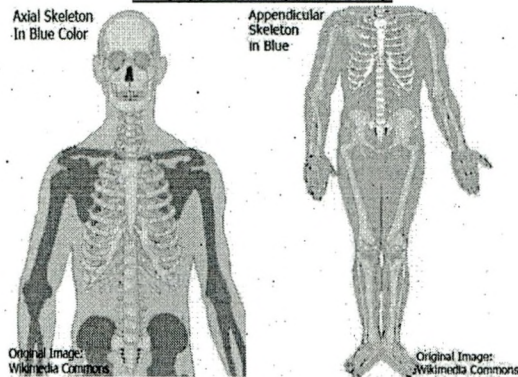


Figure 1 : Axial and Appendicular Skeleton (Source : Wikimedia Commons)

## 2.2. Functions of human skeleton

Human skeleton performs some important functions that are necessary for survival of human beings.

1. **Strength, Support and Shape:** It gives strength, support and shape to the body. Without a hard and rigid skeletal system, human body cannot stand upright, and it will become just a bag of soft tissues without any proper shape
2. **Protection of Delicate Organs:** In areas like the rib cage and skull, the skeleton protects inner soft but vital organs like heart and brain from external shocks. Any damage to these organs can prove fatal, therefore protective function of skeleton is very important
3. **Leverage for Movements:** Bones of the human skeleton in all parts of body provide attachment to the muscles. These muscles provide motor power for producing movements of body parts. In these movements the parts of skeleton acts like levers of different types thus producing movements according to the needs of the human body.
4. **Production of Red Blood Cells:** Bones like the sternum, and heads of tibia have hemopoietic activity (blood cells production). These are the sites of production of new blood cells

## 3 Bones

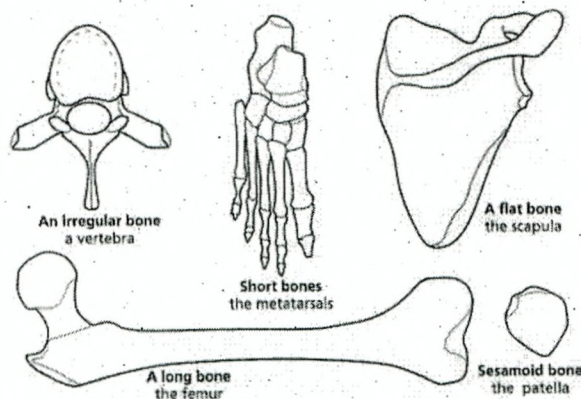
Bone is a dense type of connective tissue impregnated with inorganic salts mainly the salts of calcium such as calcium phosphate, calcium carbonate etc. The organic portion of the bone constitutes one third (1/3) and the inorganic salt component consti-

tutes two third (2/3). The inorganic salts are mainly responsible for rigidity and hardness, which make bone resist compression caused by the forces of weight and impact. The organic connective tissue portion of the bone makes it resilient and thus the bone can afford resistance to tensile forces. In strength bone is comparable to iron and steel.

The human skeleton is made up of 206 named bones and forms an important component of the skeleton of human body. Because of its rigidity and hardness, it provides the strength to keep human body in its shape. It also protects the delicate organs vital for life, for example the skull protects the brain and the ribcage protects heart and lungs. Bones are organs composed of hard living tissue that perform many functions including structural support. In different parts of the body, bone is organized in different ways, both macroscopically and microscopically. Despite their strength, bone fractures sometimes occur. Human bones are classified on different bases of classification. Generally four types of classifications are followed each dividing bones into different types.

- **Basis of Shape**

On the basis of shape, bones are classified into five different types, namely, long bones (arms, legs, hands, and feet), short bones (wrist and ankles), flat bones (Ribs, shoulder blades, hip bones and cranial bones), irregular bones (Vertebrae and facial bones) and sesamoid bones (special short bones, patella). An example for each type is shown in Figure 2.



**Figure 2 : Bone Classification According to Shape**

- **Basis of bone development**

On the basis of the pattern of development a bone follows, there are three categories, namely, membranous bones (skull and facial bones), cartilaginous bones (bones of

limbs, vertebral column and thoracic cage) and Membrocartilaginous bones (clavicle, mandible, occipital, temporal and sphenoid). Examples are shown in Figure 3.

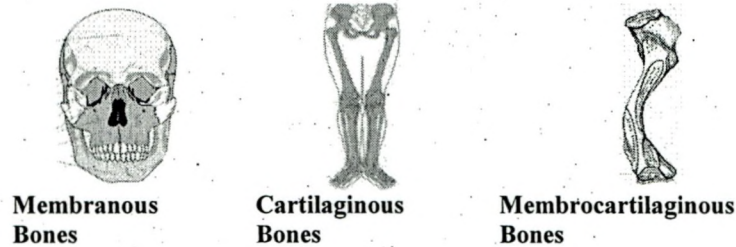


Figure 3 : Classification According to Pattern of Development

- **Basis of bone region**

On the basis of region, there are two types of bones, namely, Bones of axial skeleton and Bones of appendicular skeleton (Figure 4).

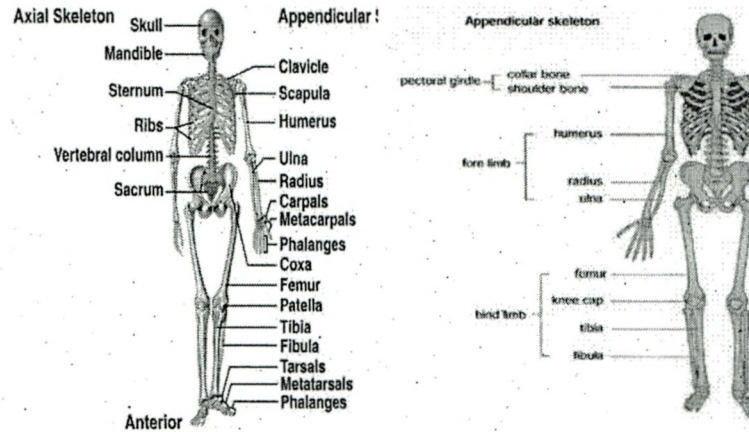
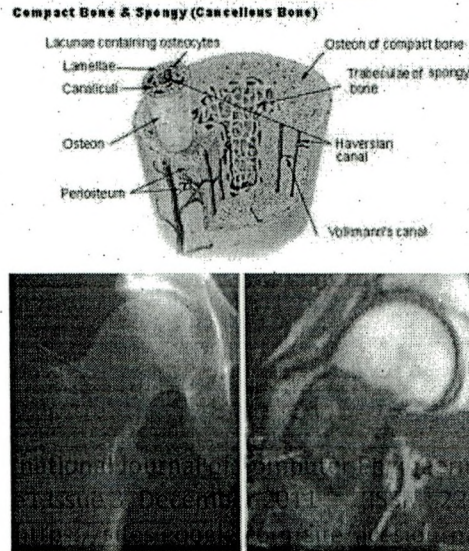


Figure 4 : Axial and Appendicular Bones

- **Basis of bone structure**

The structural classification has two approaches that are macroscopic approach and microscopic approach (Figure 5). Macroscopic approach divides the bones into two categories, Compact bone and Spongy bone. Microscopic approach divides the bones into Lamellar bone and Fibrous bone.



**Figure 5 : Classification According to Bone Structure**

**(ii) Area of Interest**

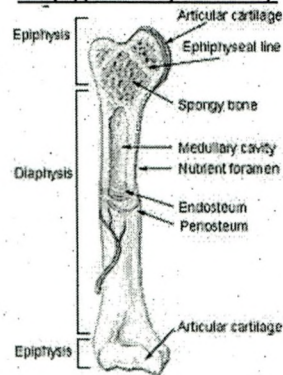
The present research work is focused on the tibia long bones. The long bones include the femurs, tibias, and fibulas of the legs, the humeri, radii, and ulnas of the arms, metacarpals and metatarsals of the hands and feet, and the phalanges of the fingers and toes. The long bones of the human leg comprise nearly half of adult height. The other primary skeletal component of height is the spine and skull. The outside of the long bone consists of a layer of connective tissue called the periosteum. Additionally, the outer shell of the long bone is compact bone, then a deeper layer of cancellous bone (spongy bone) which contains red bone marrow. The interior part of the long bone is the medullary cavity with the inner core of the bone cavity being composed of (in adults) of yellow marrow. The long-bones, such as the femur and tibia, shown in Figure 6, are tubular in structure and consist of the diaphysis, epiphysis and di-metaphysis regions.

Diaphysis

The central shaft of the long-bone is called the diaphysis. It is located between both metaphyses, consists of compact bone walls, and has a hollow medullary cavity that is filled with yellow bone marrow in adults, and red bone marrow in children. The external surface of the diaphysis is covered by the periosteum.

Epiphysis

The rounded end or head of a long-bone that consist of mostly cancellous bone covered by a relatively thin layer of cortical compact bone.



**Figure 6 : Long Bone**

**Metaphysis**

The body of cartilage that separates the epiphysis and the diaphysis. Epiphyseal plates (growth plates, or physes) are located in the metaphyses and are responsible for growth and lengthening of the bone during childhood. At roughly 18 to 25 years of age, the metaphysis stops growing altogether and completely ossifies into solid bone.

**Diametaphysis**

The region between the metaphysis and the diaphysis, where the bone shaft begins to widen and curve.

Tibia, also called as shinbone or shankbone, connects the knee with the ankle bones. It is commonly recognized as the strongest weight bearing bone in the body. It is the main bone of the lower leg and can be found on the more medial side of the leg. The tibia articulates with the femur and patella superiorly, the fibula laterally and with the ankle inferiorly. It is prismoid in form, expanded above, where it enters into the knee-joint, contracted in the lower third, and again enlarged but to a lesser extent below. In the male, its direction is vertical and parallel with the bone of the opposite side; but in the female it has a slightly oblique direction downward and lateralward, to compensate for the greater obliquity of the femur. It has a body (Diaphysis) and two extremities (Epiphysis).

**4 Fractures**

Bones form the skeleton of the body and allow the body to be supported against gravity and to move and function in the world. A typical bone ailment is the fracture, which occurs when the bone is not able to withstand outside force like direct blows, twisting injuries and falls. Fractures are cracks in bones and are defined as a medical condition in which there is a break in the continuity of the bone. Fractures can happen in a variety of ways, but there are three common causes: Trauma fractures (Accidents) [11] , Osteoporosis [8] and Stress or overuse [12]

#### 4.1. Fracture Types

In general, bone fractures can be categorized as simple or multifragmentary. Simple fractures describe a single fracture line through a bone with the broken parts still in their normal anatomical position and minimal damage to surrounding tissue, whereas the term multifragmentary refers to a fracture in which there are two or more bone fragments present.

All fractures can be broadly described as closed or open (Figure 7). Closed (simple) fractures are those in which the skin is intact and Open (compound) fractures involve wounds that communicate with the fracture, or where fracture hematoma is exposed, and may thus expose bone to contamination. Open injuries carry a higher risk of infection. A complicated fracture is a fracture of the bone combined with a lesion of an organ, artery, nerve bundle, or joint.

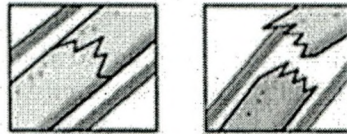


Figure 7 : Closed and Open Fracture

Fractures can also be classified as traverse fracture (fracture at a right angle to the long axis), oblique fractures (occurs at an angle to the long-bone axis), spiral fracture (runs around the axis of the bone) and greenstick (incomplete) fracture (only one side of the bone is broken). Examples are shown in Figure 8 [1]. In general, three features of a fracture are to be considered during analysis. They are,

Fracture description : A fracture can be described as either open or closed. A fracture is considered open, if the skin over the break is disrupted, else it is closed.

Fracture line : A fracture line is the description of the crack. It can be transverse (parallel to bone), oblique (at an angle) and spiral.

Fracture alignment – This gives a description as to whether the fracture fragments are displayed or in normal anatomic position.

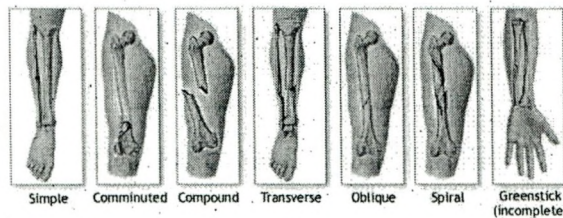


Figure 8 : Types of long-bone Fractures

#### 4.2. Tibial Fracture Types

The fracture of the diaphysis of tibia can be classified first into three group which are Simple, Wedge and Complex. For simple fracture, it will be classified into three groups which are spiral, oblique and transverse. For wedge fracture, it will be further classified into spiral wedge, Bending wedge, Fragmented wedge. For complex fracture, it will be classified into Spiral, segmental and irregular. Examples are shown in Figure 9.

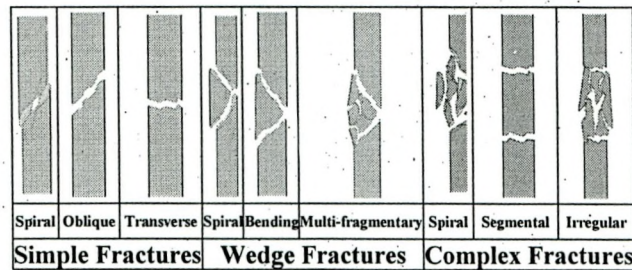


Figure 9 : Types of Tibia Diaphysis Fractures

#### 5 Conclusion

Automatic detection and treatment is given utmost priority in medical field. To develop an efficient automatic bone fracture detection and identification system, a clear understanding about the human skeletal system and fractures is required. In aid to this, this work presented a detailed description about human skeletal system, with particular emphasis given to long tibial bones. A brief discussion on the various types of fractures is also presented. In future, the techniques used in different stages of fracture detection system are to be probed and an automatic fracture detection system is being planned.

#### References

1. ADAM Healthcare Center (2006) <http://adam.about.com/encyclopedia/index.htm>, Last Access Date : May 2011.
2. Chipchase, L.S., McCaul, K. and Hearn, T.C. (2000) Hip fracture rates in South Australia: Into the next century, Australian and New Zealand Journal of Surgery, Vol. 70, No. 2, Pp. 117–119.
3. Health Care in India: Emerging market report (2007) Pricewaterhouse Coopers.
4. <http://commons.wikimedia.org>
5. <http://indiatoday.intoday.in>
6. [http://www.bcb.uwc.ac.za/Sci\\_Ed/grade10/mammal/cart.htm](http://www.bcb.uwc.ac.za/Sci_Ed/grade10/mammal/cart.htm)
7. <http://www.wikipedia.org>

8. Lee, N.K., Sowa, H., Hinoi, E., Ferroni, M., Ahn, J.D., Confavreux, C., Dacquin, R., Mee, P.J., McKee, M.D., Jung, D.Y., Zhang, Z., Kim, J.K., Mauvais-Jarvis, F., Ducy, P. and Karsenty, G. (2007) Endocrine Regulation of Energy Metabolism by the Skeleton, *Cell*, Vol. 130, No. 3, Pp. 456–469.
9. Praemer, A., Furner S. and Rice, D.P. (1992) Musculoskeletal conditions in the United States, Park Ridge, IL: American Academy of Orthopedic Surgeons.
10. Rockwood, C.A., Green, D.P. and Bucholz, R.W. (2006) *Rockwood and Green's fractures in adults*, 6th ed., Vol. 2, Lippincott Williams & Wilkins, Philadelphia.
11. Rogers, L.F., Talianovic, M.S. and Boles, C.A. (2008) Skeletal trauma,; Grainger RC, Allison D, Adam, Dixon AK, eds. *Diagnostic Radiology: A Textbook of Medical Imaging*, 5th ed. New York, NY: Churchill Livingstone; Chap 46.
12. Tamisiea D.F. (2008) Radiologic aspects of orthopedic diseases, Mercier LR, ed. *Practical Orthopedics*, 6th ed. Philadelphia, Pa: Mosby Elsevier; Chap 16.

### Authors Bibliography



Dr.S.N.Geethalakshmi working as Reader in the Department of Computer Science, Avinashilingam University for Women. She has nineteen years of teaching experience and ten years of research experience. Her area of interest is Image Processing, Software engineering. Her publications include 3 International journals, 3 National Journals, 9 International Conferences, 3 National Conferences and 2 National Articles.



N.Umadevi working as Head in the Department of Computer Science and Information Technology cum NSS Programme officer, Sri Jayendra Saraswathy Maha Vidyalaya College of Arts and Science, Singanalur, Coimbatore is a part time Research Scholar of Avinashilingam University for Women, Coimbatore doing her research under the guidance of Dr.S.N.Geethalakshmi. The Scholar has 3 years of industrial experience and 9 years of teaching experience. Her area of interest are Image Processing and Data Mining. Her publications include 3 International Jour-